



OPEN ACCESS

# Chronic ectopic pregnancy presenting as a suspected tubo-ovarian abscess: a diagnostic dilemma

Abayomi Ibukun Alao , Jaydip Dasgupta, Bivas Biswas

Obstetrics and Gynaecology,  
Royal Derby Hospital, Derby, UK

Correspondence to  
Dr Abayomi Ibukun Alao;  
abayomi.alao@nhs.net

Accepted 23 December 2022

## SUMMARY

Though there is no definite agreement on diagnostic criteria or definition of chronic ectopic pregnancy (CEP), it could be deemed to be a variant of pregnancy of unknown location with non-specific clinical signs and symptoms. This was a case of a para 2+2 who presented with lower abdominal pain and bleeding per vaginum, and initial ultrasound was suggestive of a tubo-ovarian abscess/mass. With a further MRI scan and a diagnostic laparoscopy, she was found to have a CEP and had a laparoscopic salpingectomy for management. The diagnosis of CEP could be quite challenging as a result of the protracted symptoms, often negative/low serum B-HCG and ultrasound features mimicking a pelvic mass. A high index of suspicion is needed, and an MRI scan and diagnostic laparoscopy often aid in diagnosis and management.

## BACKGROUND

An ectopic pregnancy (EP) occurs when the gestational sac is implanted outside of the endometrial cavity.<sup>1</sup> An absolute majority of cases of ectopic pregnancies are implanted in the fallopian tube and present clinically with symptoms of amenorrhoea, lower abdominal pain and vaginal bleeding.<sup>2</sup> Chronic EP (CEP) is a variant of EP, which is difficult to diagnose with variable and non-specific clinical signs and symptoms<sup>3</sup> and there remains no universal agreement about the definition of CEP. Often it is a retrospective diagnosis considering the clinical presentation and intra operative findings.<sup>4</sup> Serum B-HCG, which is a reliable marker in monitoring as well as establishing a diagnosis of EP, tends to remain low or negative in CEP due to sparse chorionic villi, adding further challenges to making the diagnosis.<sup>5</sup> CEP often develops when the trophoblastic tissue gradually invades through the implantation site leading to repeated rupture

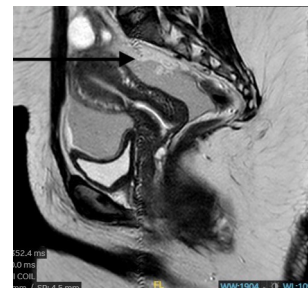


Figure 2 MRI of the pelvis.

at the site and continued minor bleeding that over time can develop into a haematocele and appear as a pelvic mass.<sup>5</sup> The exact incidence of CEP is difficult to ascertain due to the varied criteria for definition, adopted in literature.<sup>3</sup> However, the final diagnosis of CEP is often made at histology with findings of haemorrhage and blood clots, disintegration of the tubal wall, multiple minor ruptures, and areas of dense fibrosis and necrosis embedded within degenerated and/or avital chorionic villi.<sup>3</sup>

## CASE PRESENTATION

A para 2+2 presented to the gynaecology assessment unit with a 4-day history of severe lower abdominal pain associated with mild PV bleeding, which was presumed to be normal periods. She had had a spontaneous miscarriage 4 weeks prior and her serum B-HCG levels had dropped from 700 IU/L to 400 IU/L and 3 weeks postmiscarriage urine pregnancy test was negative. She had no history of similar pain, no history of dysmenorrhoea, no bowel or urinary symptoms or previous pelvic inflammatory disease or use of intrauterine contraceptive device.

On examination, there was localised tenderness in the right iliac fossa, there was no guarding or rebound tenderness, pelvic examination show a healthy looking cervix minimally smeared with altered blood, there was no cervical motion tenderness. Her blood results revealed a haemoglobin of 101 g/L, a C reactive protein of 25 mg/L, normal urea and electrolytes and a serum B-HCG of 3 IU/mL. Transvaginal pelvic ultrasound (figure 1) showed a heterogeneous mass in the right adnexa measuring 32×29×61 mm, suggestive of a tubo-ovarian abscess/mass.

She was admitted and was started on conservative management with intravenous antibiotics and analgesia with a view for consideration of a diagnostic laparoscopy, if there was no clinical improvement. Tumour markers which were normal and an MRI pelvis (figure 2) showed large amounts of

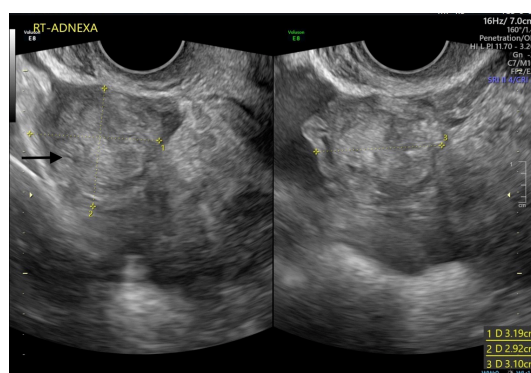
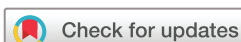

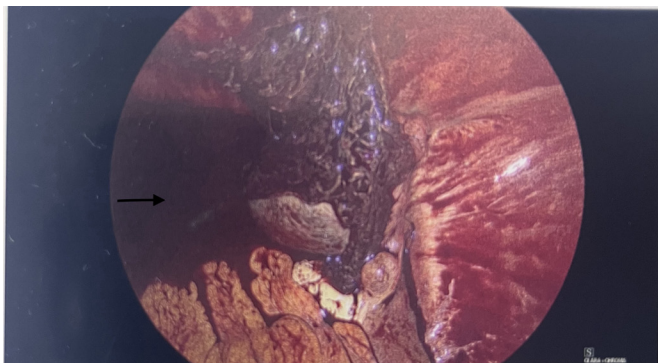
Figure 1 Transvaginal ultrasound showing pelvic mass.



© BMJ Publishing Group Limited 2023. Re-use permitted under CC BY-NC. No commercial re-use. See rights and permissions. Published by BMJ.

To cite: Alao AI, Dasgupta J, Biswas B. *BMJ Case Rep* 2023;**16**:e253396. doi:10.1136/bcr-2022-253396

## Case report



**Figure 3** Laparoscopic view showing intra-abdominal haemorrhage.

fluid, possible blood in the pelvis and a right adnexal structure adjacent to the uterus.

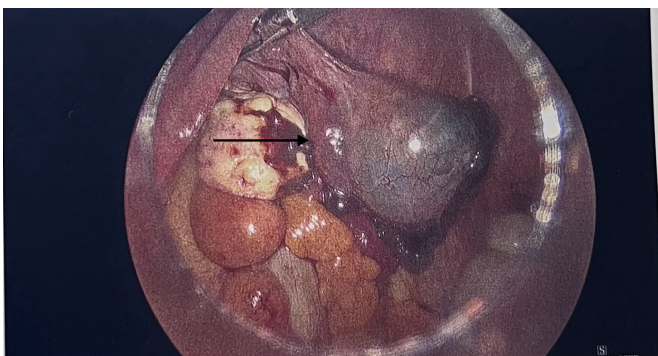
She went on to have a diagnostic laparoscopy with a proceed to right salpingectomy and a peritoneal lavage. Intraoperatively, there was about 50 mL of haemoperitoneum (**figure 3**) all over the abdomen and in the pelvis, a right ampullary swelling suggestive of ectopic with an unhealthy right tube stuck to the anterior abdominal wall (**figure 4**), the tube with the ectopic were excised and the tissue retrieved using an Endo catch retrieval bag through the 10 mm suprapubic port. The uterus, right and left ovaries were all normal. Histology of the specimen showed fallopian tube containing immature chorionic villi, intermediate trophoblast, blood and fibrin, supporting a diagnosis of a CEP.

### DISCUSSION

CEP is a rare and challenging diagnosis, with few cases reported in literature,<sup>4</sup> and often presents with similar symptoms to an EP, namely amenorrhoea, lower abdominal pain and vaginal bleeding. However, because of the protracted nature of symptoms and often negative B-HCG (Beta- Human chorionic gonadotropin) as a result of inactive or avital trophoblast in women with CEP it often poses a diagnostic dilemma.<sup>4</sup> The most common presenting symptom of women with CEP is abdominal pain, followed by irregular vaginal bleeding, and fever.<sup>3</sup> An ultrasonographically visible adnexal mass at the time of the initial diagnosis is usually found in about half of cases of CEP.<sup>3</sup>

The diagnosis of an acute EP is made using a combination of clinical findings, laboratory investigations and ultrasonography.<sup>1 6 7</sup> Ultrasound scan is not as effective in diagnosing a CEP, as was the case in index patient, with an initial ultrasound differential diagnosis of a possible tubo-ovarian abscess/mass.<sup>1</sup>

CEP develops when the implanted trophoblastic tissue invades the fallopian tube, leading to a gradual destruction at the site



**Figure 4** Laparoscopic view of the pelvis.

### Patient's perspective

- ▶ This is an important section and gives the patient/next of kin the opportunity to comment on their experience. This enhances the case report and is strongly encouraged. This section is written by the patient (or close family) in their own words, in the first-person. This is an opportunity for us to understand the signs and symptoms the patient experienced, their thoughts and concerns, their experience of the treatment they received, recovery and adjustment to life after or with illness or disability.
- ▶ Spelling and grammar should be corrected where necessary (as per the rest of the manuscript) by the authors and non-English perspectives should be translated by the authors. Please make clear who has written the perspective and indicate when this has been translated by the authors. Patient who prefer to share an audio or video perspective should have this transcribed by the authors. For the purposes of anonymity audio and video recordings are not published.
- ▶ Please check that details that reveal the identity of the patient are avoided. These include calendar dates, locations and details of other family members.
- ▶ Some published articles are picked up by the wider non-medical media and patients should be made aware of this, especially, when they contribute their perspective and when they give consent for publication.

### Learning points

- ▶ A high index of suspicion is necessary, and an MRI scan and diagnostic laparoscopy aids in diagnosis and management.
- ▶ The management of choice for a chronic ectopic pregnancy is a laparoscopy and salpingectomy as it is often difficult to perform conservative surgery due to extensive damage of the tube and the severity of pain symptoms.

of implantation which results in repeated rupture and minor bleeding.<sup>2</sup> This repeated bleeding eventually forms a haematocoele, which causes inflammatory changes which can then appear as a chronic inflammatory pelvic mass on diagnostic imaging.<sup>2</sup> MRI scans can be helpful in the diagnosis of CEP with features such as presence of a haemoperitoneum associated with haematosalpinx and prominent enhancement of the tubal walls, suggestive of a CEP with the concurrent presence of a pelvic mass, as was evident in the findings in our case. However, MRI scans are limited in their availability, depending on the geographical location of the patient as well as not absolutely essential in the diagnostic armamentarium. The management of choice for a CEP is a laparoscopy and salpingectomy as it is often difficult to perform conservative surgery due to extensive damage of the tube and the severity of pain symptoms and a high index of suspicion is often warranted. CEP is often resistant to methotrexate, and this could be due to the low amount of active chorionic villi and minimal or absent trophoblast activity.<sup>3</sup>

**Contributors** AIA: original manuscript writing, manuscript review and editing. JD: manuscript review and editing. BB: manuscript review and editing, operating surgeon.

**Funding** The authors have not declared a specific grant for this research from any funding agency in the public, commercial or not-for-profit sectors.

**Competing interests** None declared.

**Patient consent for publication** Consent obtained directly from patient(s).

**Provenance and peer review** Not commissioned; externally peer reviewed.

**Open access** This is an open access article distributed in accordance with the Creative Commons Attribution Non Commercial (CC BY-NC 4.0) license, which permits others to distribute, remix, adapt, build upon this work non-commercially, and license their derivative works on different terms, provided the original work is properly cited and the use is non-commercial. See: <http://creativecommons.org/licenses/by-nc/4.0/>.

Case reports provide a valuable learning resource for the scientific community and can indicate areas of interest for future research. They should not be used in isolation to guide treatment choices or public health policy.

#### ORCID iD

Abayomi Ibukun Alao <http://orcid.org/0000-0003-1300-6535>

#### REFERENCES

- 1 Nacharaju M, Vellanki VS, Gillellamudi SB, *et al*. A rare case of chronic ectopic pregnancy presenting as large hematosalpinx. *Clin Med Insights Reprod Health* 2014;8:CMRH.S13110–4.
- 2 Al Kindi N, Al Shalabi F, Kapadia S, *et al*. A case report and a literature review: a challenging case of chronic tubal ectopic pregnancy. *MOJ Women's Health* 2021;10:5–6.
- 3 Tempfer CB, Dogan A, Tischoff I, *et al*. Chronic ectopic pregnancy: case report and systematic review of the literature. *Arch Gynecol Obstet* 2019;300:651–60.
- 4 Drakopoulos P, Pluchino N, Yaron M, *et al*. Chronic tubal ectopic pregnancy: a rare but challenging diagnosis. *BMJ Case Rep* 2014;2014:bcr2014205715.
- 5 O'Neill D, Pounds R, Vella J, *et al*. The diagnostic conundrum of chronic ectopic pregnancy: a case report. *Case Rep Womens Health* 2018;20:e00086.
- 6 NICE. *Ectopic pregnancy and miscarriage: diagnosis and initial management*. Natl Institute Heal Care Excell, 2015.
- 7 Elson CJ, Salim R. Diagnosis and management of ectopic pregnancy: Green-top guideline No. 21. *BJOG* 2016;123:e15–55.

Copyright 2023 BMJ Publishing Group. All rights reserved. For permission to reuse any of this content visit <https://www.bmj.com/company/products-services/rights-and-licensing/permissions/>  
BMJ Case Report Fellows may re-use this article for personal use and teaching without any further permission.

Become a Fellow of BMJ Case Reports today and you can:

- ▶ Submit as many cases as you like
- ▶ Enjoy fast sympathetic peer review and rapid publication of accepted articles
- ▶ Access all the published articles
- ▶ Re-use any of the published material for personal use and teaching without further permission

#### Customer Service

If you have any further queries about your subscription, please contact our customer services team on +44 (0) 207111 1105 or via email at [support@bmj.com](mailto:support@bmj.com).

Visit [casereports.bmj.com](http://casereports.bmj.com) for more articles like this and to become a Fellow