




A Presentation of Neurocysticercosis as a Stroke Mimic

- Aimee Rowe, Foundation Year 2 Trainee
- Reza Ghasemi, Clinical Research Fellow and SpR GIM (Acute)
- Timothy England, Consultant Stroke Physician

Royal Derby Hospital, Derby DE22 3NE, UK



- 62 year old Nepalese gentleman presented to the CDU (Clinical Decision Unit) at RDH (Royal Derby Hospital) with weakness and numbness in his left leg
- **Duration of symptoms:** 16 hours
- **Onset and progress:** Sudden onset and then symptoms plateaued

- No dysphasia
- No LOC
- No confusion
- No problems with swallowing
- No visual disturbance
- No facial droop

- PMH: Nil
- DH: Nil
- SH:
 - Native to Nepal
 - Worked most of his life as a Gurkha and travelled worldwide
 - Came to the UK two years previously
 - Travelled to Nepal regularly.

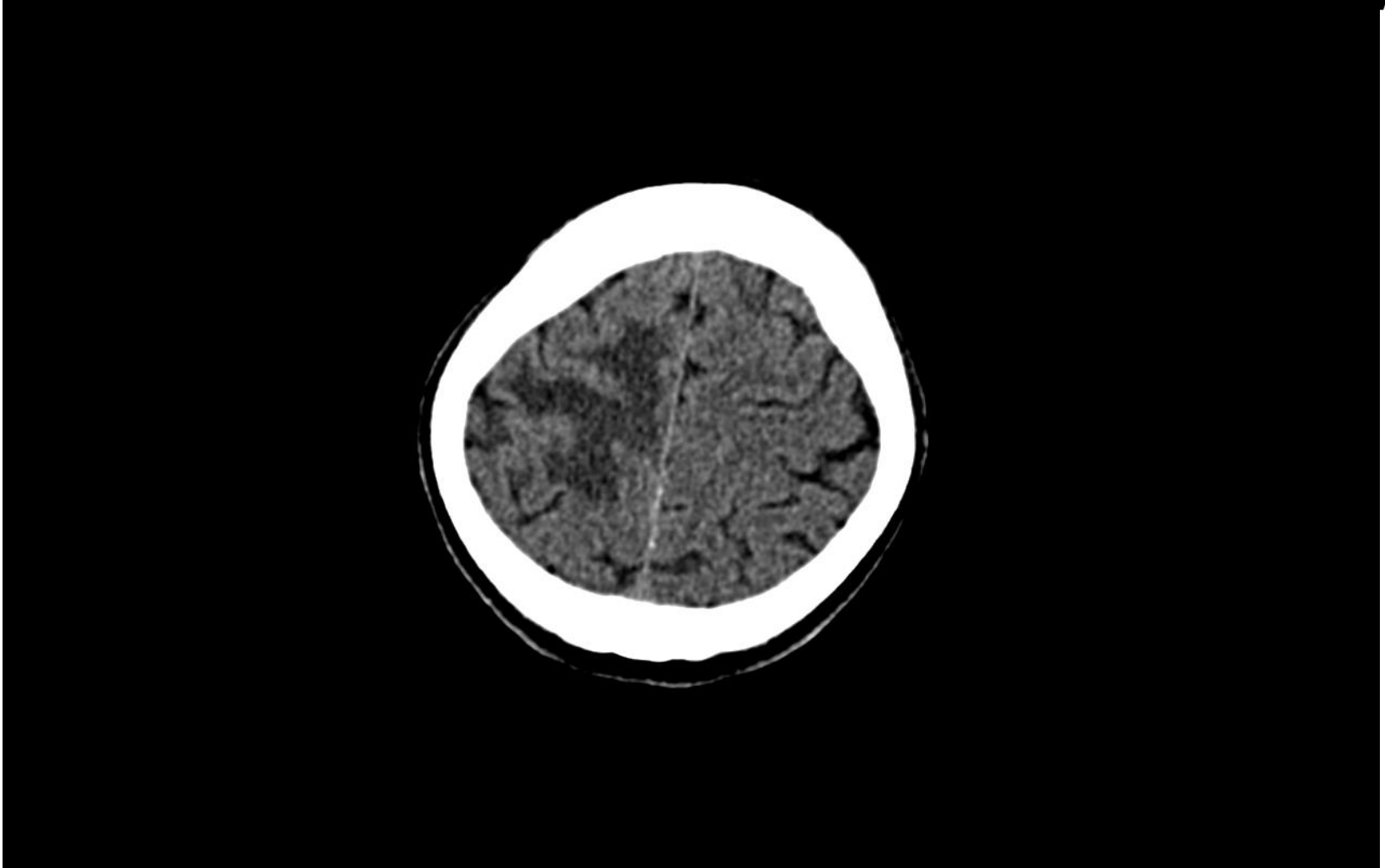- No lymphadenopathy
- Normal heart sounds
- Normal vesicular breath sounds
- Abdomen soft and non-tender
- Normal peripheral vascular examination

- **Motor:** Reduced power in left leg (MRC 2/5)
- **Sensory:** Reduced sensation to sharp and to fine touch to left leg
- **Plantar reflex:** Up going left plantar response (Positive Babinski sign)
- **Gait:** Hemiplegic gait

- Late presentation of Ischemic Stroke affecting anterior cerebral circulation

- SOL (Space Occupying Lesion)
 - ? Primary Brain Tumour
 - ? Metastases

- **ECG:** Normal
- Routine **Bloods:** Normal
- Inflammatory markers: Normal
- Urgent **CT Brain** arranged



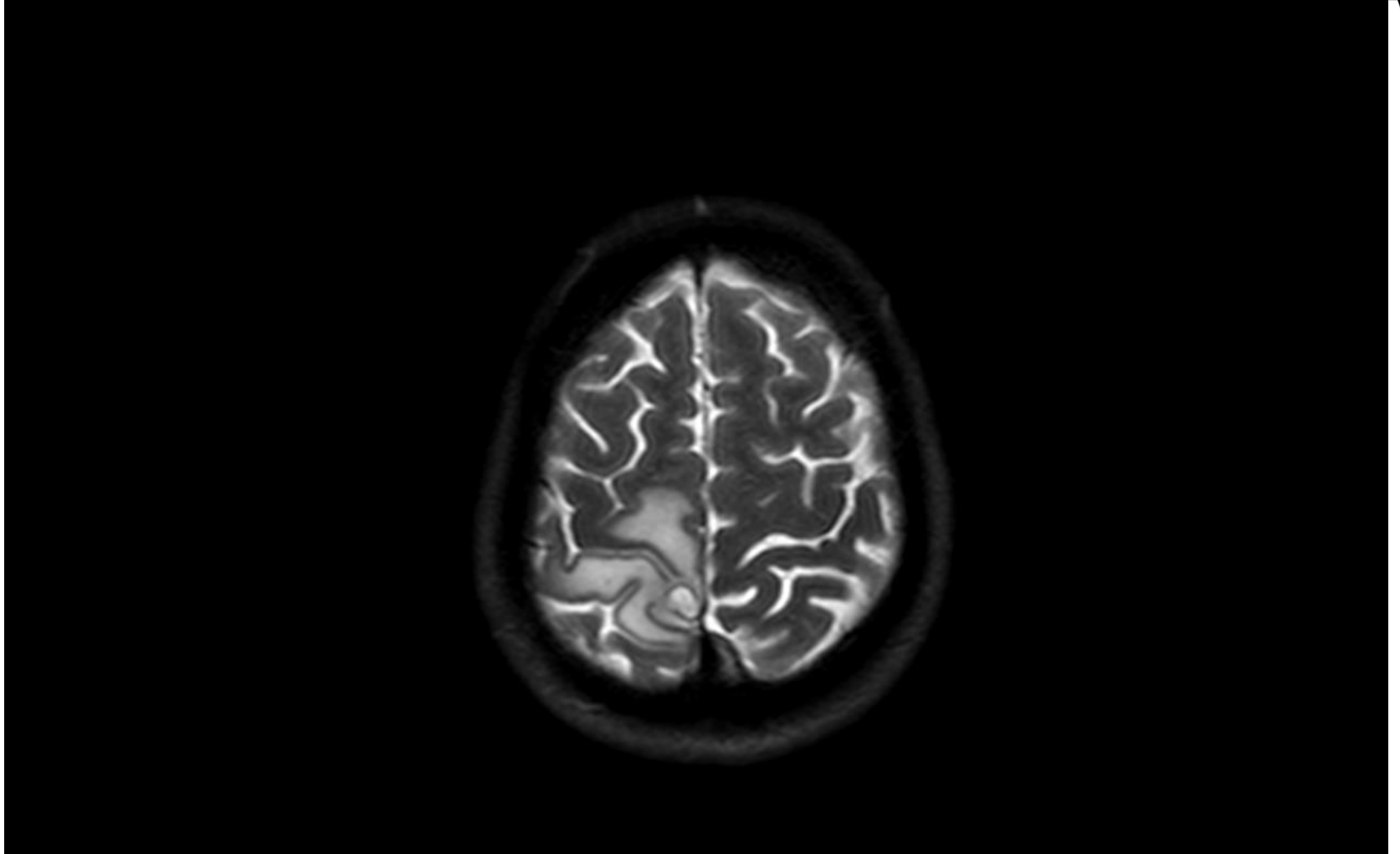
- An extensive area of low attenuation change
 - High in the right frontal and parietal lobes
 - Some sparing of the overlying cortex.
-
- Consistent with the appearance of acute ischaemic change
-
- In keeping with the clinical picture

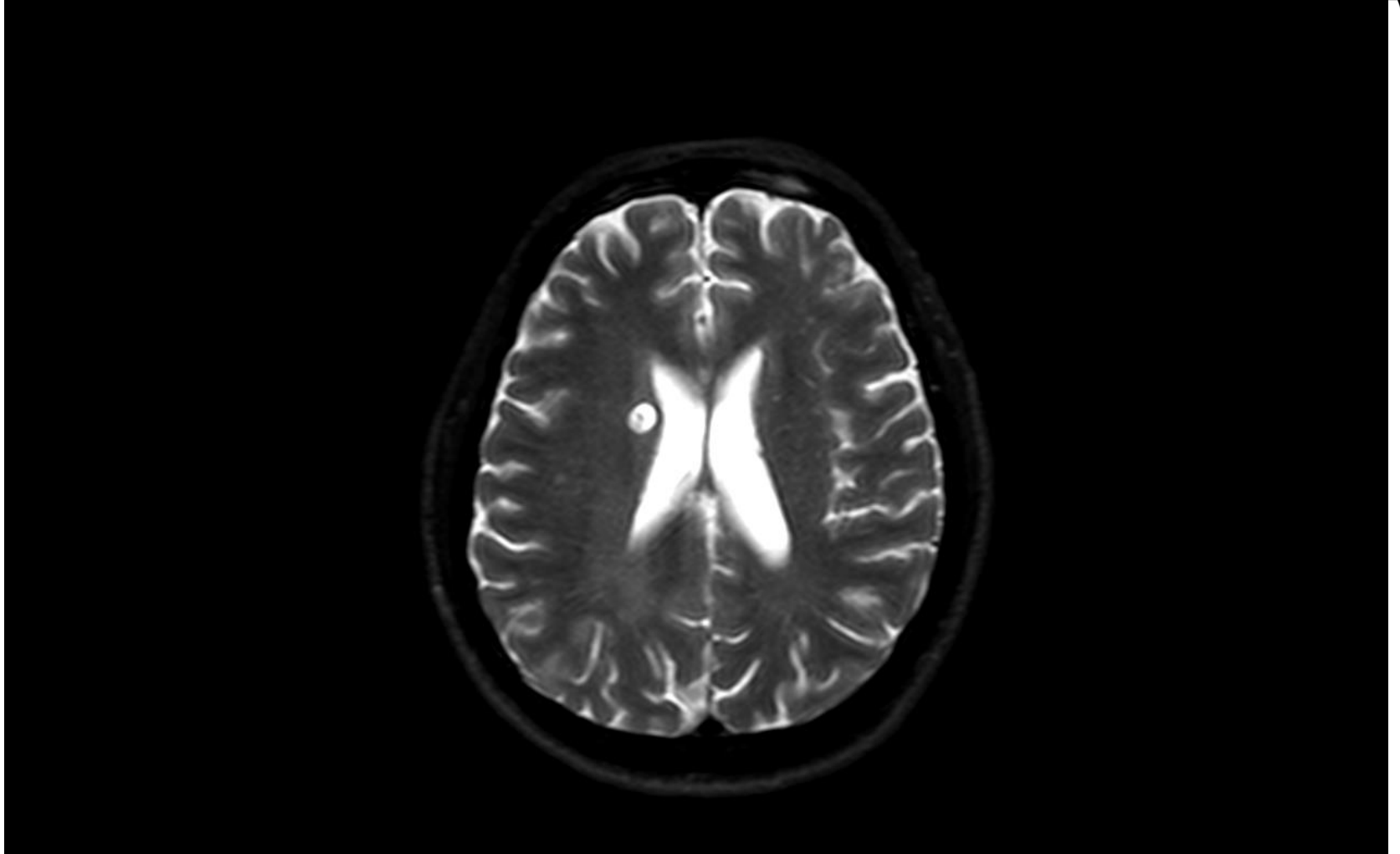


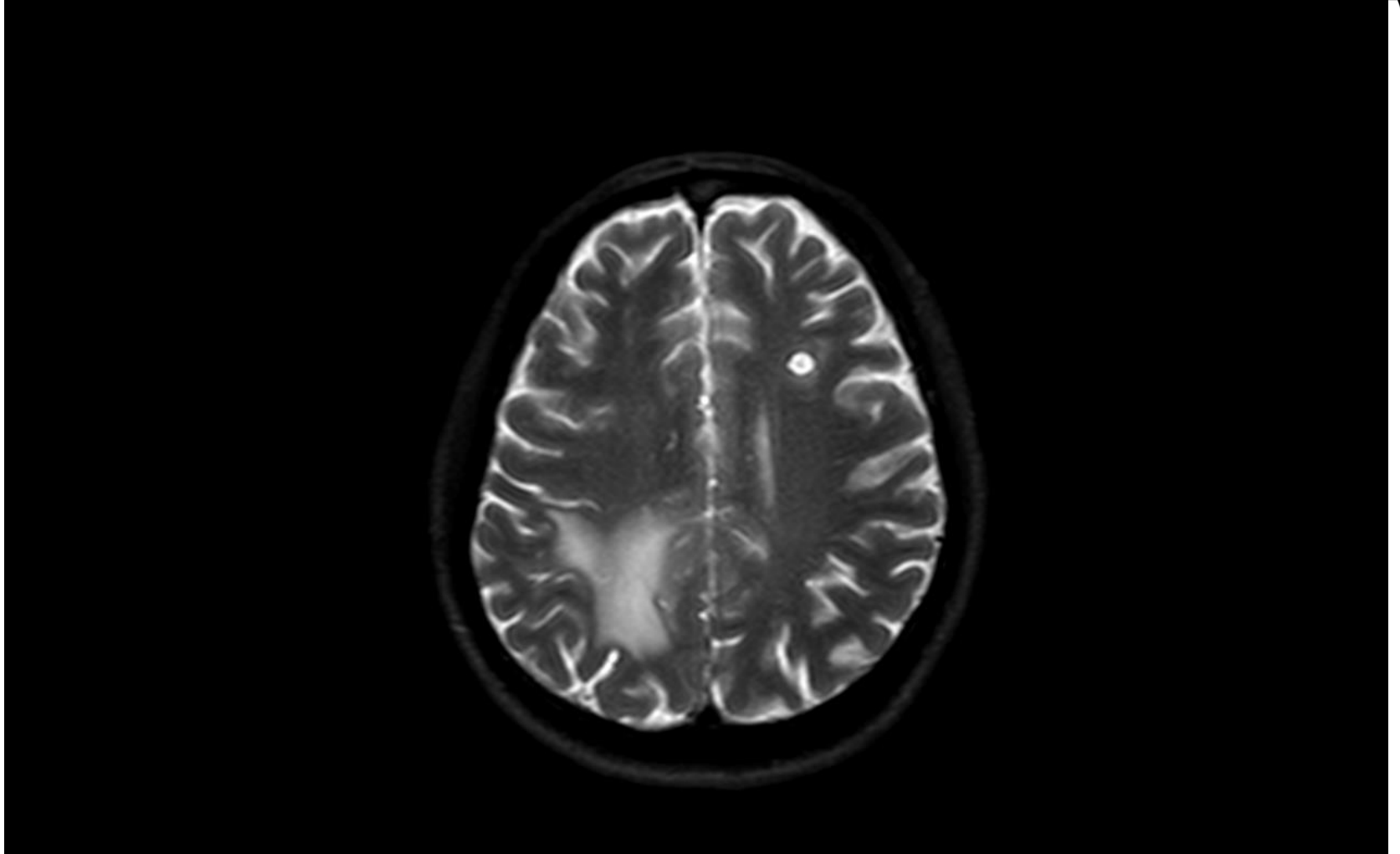
Review by Stroke Team

sam
D•A•M

- Patient was admitted to the Stroke unit at RDH
- Decided to do a MRI on the patient for the following reasons:
 1. The large size of the changes on the CT
 2. Patient's background
 3. The fact that patient was out of the 4.5 hour thrombolysis window







- Small cystic lesion in the head of right caudate nucleus
- Small cystic lesion in the head of left frontal lobe
- Largest lesion situated medially in right parietal lobe with surrounding cerebral oedema (These were the changes seen on the CT)
- The lesions have low density centres and appearances are suggestive of Neurocysticercosis



Further Investigations

sam
D•A•M


- **CT scan** of the abdomen and pelvis: two simple cysts in the liver
- **HIV** testing, **Syphilis** serology and Quantiferon **TB** Gold In-Tube (QFT-GIT) testing were negative
- Serum enzyme-linked **immuno**electrotransfer **blot** for the detection of anti-cysticercal antibodies: **positive**



Management

sam
D•A•M


- Discussed with the regional ID team
- **Seizure prophylaxis:**
Levetiracetam 250 mg BD
- **Anti-helminthics:**
Albendazole 400 mg BD
Praziquantel 1000 mg TDS
- **Management of oedema:**
Prednisolone 40 mg OD



After 2 weeks

sam
D•A•M


- Patient C/O occasional headaches
- Power of left leg improved to MRC 4/5
- Sensation only reduced distal to his mid-shin



After 2 months

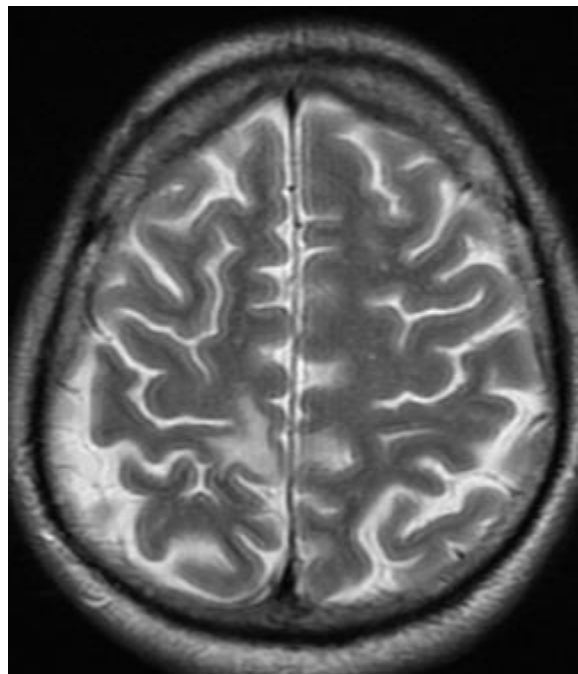
sam
D•A•M


- Patient completely asymptomatic
- Motor power returned to normal
- Residual sensory loss confined to the sole of the foot



After 2 months

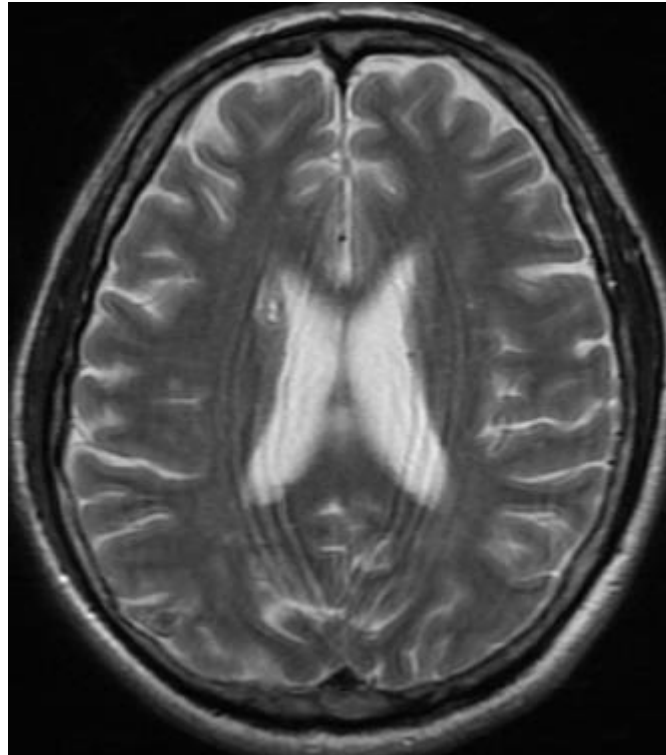
sam
D•A•M






After 2 months

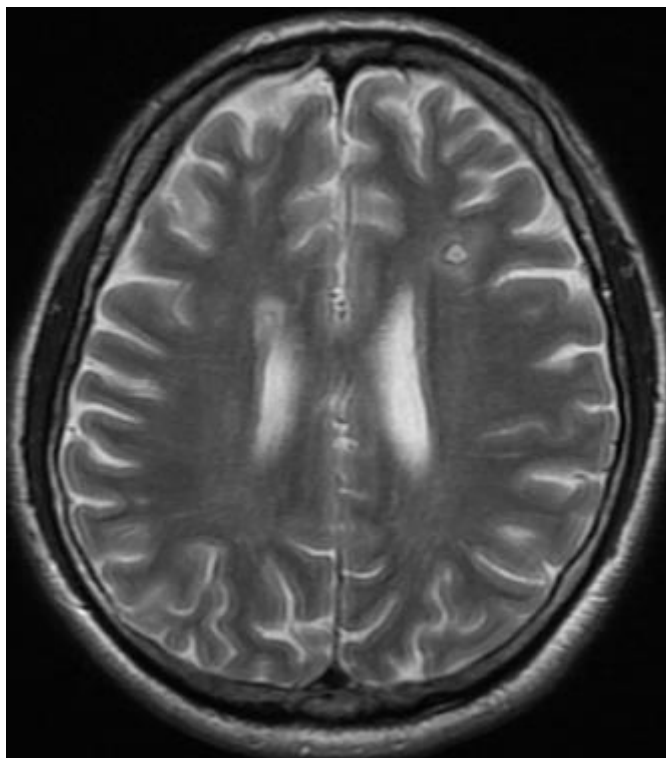
sam
D•A•M





After 2 months

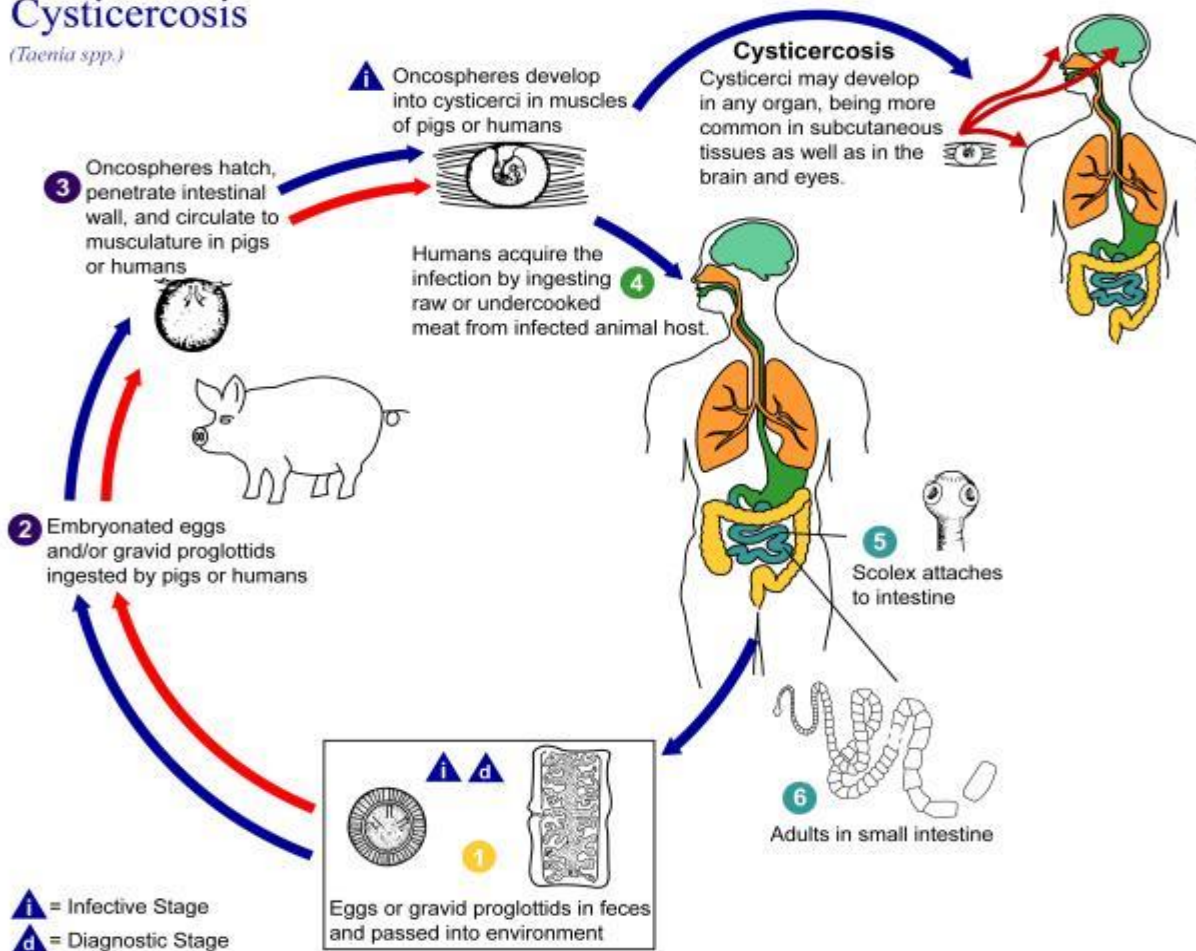
sam
D•A•M




Cysticercosis Cycle

Taenia Solium
(Pork
Tapeworm):

Cysticercosis (*Taenia spp.*)






Neurocysticercosis (NCC)

sam
D•A•M


- Most common parasitic infection of the CNS
- Most common cause of Epilepsy worldwide
- Common throughout Asia, Sub-Saharan Africa and Latin America



Presentation of NCC

sam
D•A•M

- Epilepsy
- Brown Sequard Syndrome
- Acute Hydrocephalus due to intraventricular NCC
- Ischemic Stroke due to vascular occlusion
- Brain haemorrhage due to rupture of mycotic aneurysms
- Stroke mimic (rare)




NCC in the UK

sam
D•A•M

- Rare in the UK, with all cases being acquired outside the country
- Most cases seen in London
- When it does present in the UK, epilepsy is the most common manifestation

- **Indications for Testing:** Requires high index of suspicion in non-endemic areas
- **Criteria for Diagnosis:**
Proposed diagnostic criteria for human cysticercosis:
 - **Absolute, Major, Minor and Epidemiologic** criteria




- Key for diagnostic interpretation:
 - **Confirmation**
 - 1 absolute criterion
 - 2 major, 1 minor, and 1 epidemiologic criteria
 - **Probable**
 - 1 major and 2 minor
 - 1 major, 1 minor, and 1 epidemiologic
 - 3 minor and 1 epidemiologic

1. Demonstration of cysticerci by histologic or microscopic examination of biopsy materials
2. Visualization of the parasite in the eye by funduscopy
3. Neuroradiologic demonstration of cystic lesions containing a characteristic scolex

1. Neuroradiologic lesions suggestive of NCC
2. Demonstration of antibodies to cysticerci in serum by enzyme-linked immunoelectrotransfer blot
3. Resolution of intracranial cystic lesions spontaneously or after therapy with albendazole or praziquantel

1. Lesions compatible with NCC detected by neuro-imaging studies
2. Clinical manifestations suggestive of NCC
3. Demonstration of antibodies to cysticerci or cysticercal antigen in CSF by ELISA
4. Evidence of cysticercosis outside the CNS (eg, cigar-shaped soft-tissue calcifications)

1. Residence in a cysticercosis-endemic area
2. Frequent travel to a cysticercosis-endemic area
3. Household contact with an individual infected with *Taenia solium*



Diagnosis in our case

sam
D•A•M

Major criteria:

- highly suggestive imaging, positive serum antibody testing and response to anti-parasitic treatment

Minor criteria:

- compatible imaging and clinical manifestation

Epidemiologic criteria:

- native to endemic area and travel to endemic area



Learning points (1)

sam
D•A•M

- **Making decisions on thrombolysis in acute stroke cases:**
- Thrombolysis is licensed in acute ischemic stroke patients presenting within 4.5 hours (No age limits)
- In our patient thrombolytic treatment might have had serious untoward consequences if he had presented within 4.5 hours
- Pay attention to Stroke mimics when considering thrombolysis in acute stroke cases

- **Imaging in stroke:**
- First screening is with CT and not MRI scanning and would understandably have been interpreted as acute infarction
- It is not possible to confirm the diagnosis of NCC acutely and one is dependent on radiological clues, this case illustrating the limitations of CT scanning
- Be aware of CT scan limits

- **Stroke mimics as differential diagnoses; History is important:**
- Migration from endemic to non-endemic areas is increasing. The patient's background might raise suspicion of stroke mimics and therefore NCC.
- Pay attention to patient's background, travel history and social history


- The case reminds us to consider not just NCC but other stroke mimics in the differential diagnosis of acute stroke, especially in the thrombolysis window period (the first 4.5 hours)



References

sam
D•A•M

- Patel R, Jha S, Yadav RK. Pleomorphism of the clinical manifestations of neurocysticercosis. *Transactions of the Royal Society of Tropical Medicine and Hygiene* 2006;100:134-41.
- Wadley JP, Shakir RA, Rice Edwards JM. Experience with Neurocysticercosis in the UK: correct diagnosis and neurosurgical management of the small enhancing brain lesion. *Br J Neurosurg.* 2000 Jun;14(3):211-8
- Marquez JM, Arauz A. Cerebrovascular complications of neurocysticercosis. *Neurologist* 2012;18:17-22.
- Bang OY, Heo JH, Choi SA, Kim DI. Large cerebral infarction during praziquantel therapy in neurocysticercosis. *Stroke* 1997;28:211-3.



Thank you

sam
D•A•M

